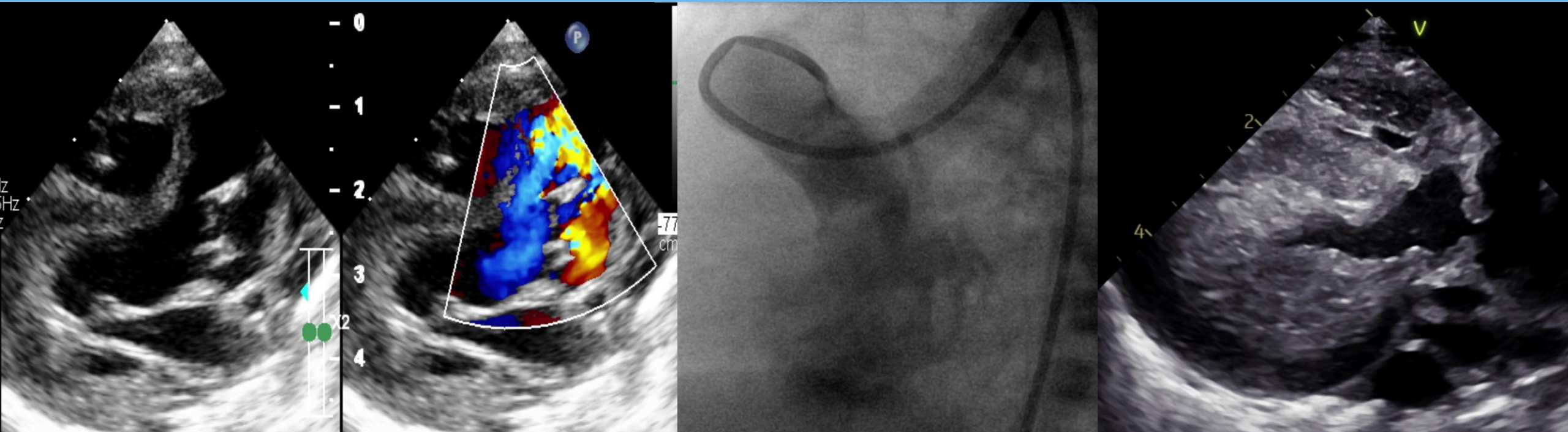


# Aorto - Left ventricle tunnel combined with severe aortic valve stenosis and large PDA



Neonate 2.5kg with large type II ALVT, underestimated severe aortic valve stenosis and large PDA, was early presented heart failure. Surgical or device closure for PDA and ALVT without suitable stenotic aortic valve repair may expose the AS and accelerate myocardial hypertrophy.